

# MAGNETIC RESONANCE IMAGING (MRI) STUDY: SIMULTANEOUS FAT AND MUSCLE EFFECT

HIGH INTENSITY FOCUSED ELECTRO-MAGNETIC THERAPY (HIFEM®) EVALUATED BY MAGNETIC RESONANCE IMAGING (MRI): SAFETY AND EFFICACY STUDY OF A DUAL TISSUE EFFECT BASED NON-INVASIVE ABDOMINAL BODY SHAPING.

Brian M. Kinney M.D. FACS<sup>1</sup>, Paula Lozanova M.D.<sup>2</sup>

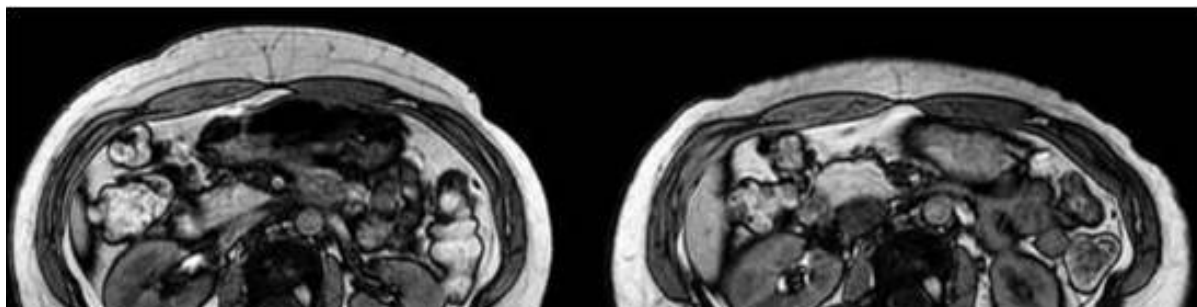
1. Plastic Surgery Excellence, Beverly Hills CA, USA; 2 Paula Fines Center, Sofia BG, Europe

Presented at the Annual Meeting of the American Society for Laser Medicine and Surgery, 2018 Dallas, TX.

---


## HIGHLIGHTS

- **22 patients** were evaluated **2 months after four 30-min treatments**.
  - Abdominal **fat thickness was reduced on average by 18.6 %** or 4.3 mm.
  - Abdominal **muscle mass increased on average by 15.4 %**, coupled with a **10.4 % average reduction in diastasis recti**.
  - Waist circumference decreased on average by **1.4 inch**.
- 



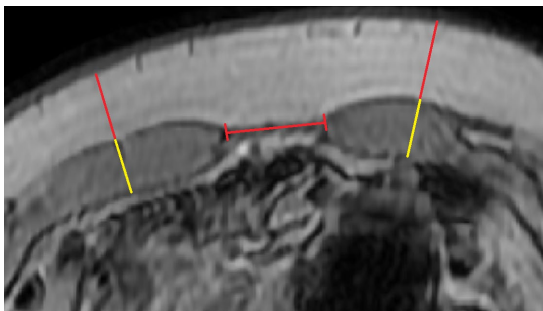
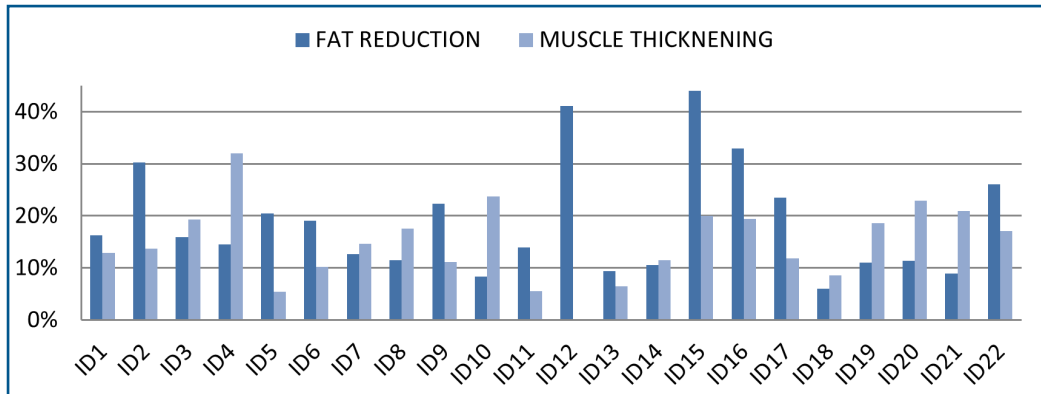
BASELINE

2 MONTH FU

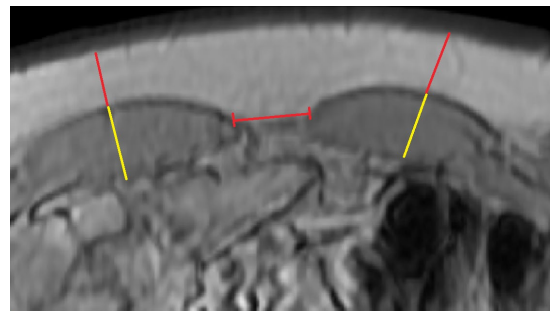


## RESULTS

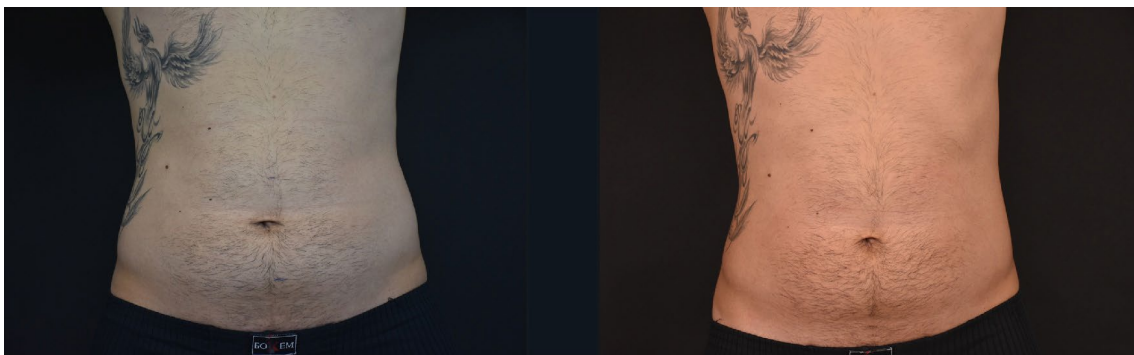
- No adverse event. Several patients reported mild muscle fatigue which resolved within 12-48 hours.
- Simultaneous reduction in subcutaneous fat and strengthening of abdominal muscles in treated patients evaluated by MRI.



BASELINE



2 MONTH FU



Tissue changes 2-months post-treatment (right) versus baseline (left) captured by magnified MRI cuts. The patient showed 30.2% reduction in subcutaneous fat thickness (upper red lines) and 14% thickening of rectus abdominis (yellow lines) compared to baseline. This tissue re-composition was coupled with a 24.9% reduction in the lateral sinister/dexter distance (middle red line segment). Subject ID2, aged 30, weight change -2.2 lbs (-1.2%).